

The use of the Ambu Aura-i SupraGlottic airway in an iSGA-first rescue strategy

A560
ASA 2011

Søren B. Laursen, M.D. ¹; Frank Samsøe Jensen, M.D. ²; Anette Kristiansen, C.R.N.A.; Nazarena Mazzaro, Ph.D.;
¹ Private Hospital Arresødal, Copenhagen Denmark ² Copenhagen University Hospital Gentofte, Copenhagen Denmark

Introduction

In the clinical scenario of can not intubate/can not ventilate (CICV) a technically easy and readily available method of securing the airway is vital. The ability to rapidly intubate the trachea through an insitu SGA has the advantage of allowing ventilation before and during intubation attempts. Although the use of an SGA for the purpose of elective or emergency intubation is not new, most methods described in the literature employ the placement of a variety of exchange catheters through standard SGAs which were designed for noninvasive ventilation only. There are also SGAs designed for blind intubation; however the intubation rate achieved is low^{4,5,6}. We describe a method of elective or rescue orotracheal intubation using the new Ambu Aura-i SGA (Ambu A/S Denmark) and the Ambu aScope (single use flexible optical scope) to ensure correct placement of the orotracheal tube. We refer to this concept as an iSGA-first strategy: in this strategy, the elective or emergent use of an intubation-capable SGA allows the rapid conversion to tracheal intubation if needed.

Methods

Thirty-five patients with no predictors of difficult intubation nor ventilation, scheduled for elective surgery were included. An Ambu Aura-i was used for maintenance of anaesthesia management in all cases. For a subset of patients in whom the clinician elected tracheal intubation, an Ambu aScope with a pre-loaded tracheal tube was inserted through the Aura-i and into the larynx. Data regarding insertion success, ease of insertion of the Aura-i, seal pressure, optical view with the aScope, and success of intubation were collected. Ease of insertion was scored on a 5 level scale (1 = very easy, 2 = fairly easy, 3 = difficult, 4 = very difficult and 5 = not possible). Seal pressure was measured in cm H₂O. A POGO laryngeal view score^{1,2} was measured once the Ambu aScope was placed at the SGA opening.

Results

The Ambu Aura-i was inserted at 1st attempt in 34 patients. In one case the SGA had to be replaced to a smaller size. Ease of insertion of the Aura-i was evaluated as "very easy" in 32 patients and "fairly easy" in 2 patients. The average Aura-i seal pressure was 25,2 cm H₂O (16 – 35 cm H₂O). In the 21 patients who were intubated with the use of the aScope, the POGO score was rated; 1/30, 1/70% and 19/100% (table 1). Intubation was successful on the first attempt in all 21 patients.

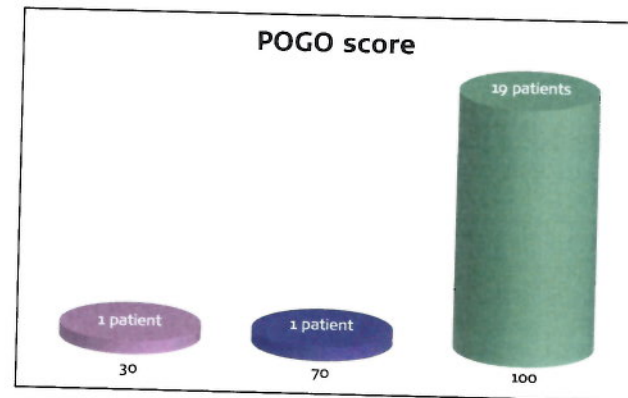


Table 1: Nine-teen patients scored 100% POGO, one 70% and one 30%

Conclusion

The Ambu Aura-i performed satisfactory both as a ventilatory device and as a conduit for flexible scope aided intubation.

Management of an unanticipated difficult airway by flexible optical guided intubation using an SGA as a conduit is attractive because it may allow unhurried optical instrumentation of the airway with a minimal interruption of oxygenation and ventilation.

Discussion

Failure of first airway approaches may lead to temporary hypoxemia. Depending on the skill level of the clinician and availability of alternative intubation devices, some of these hypoxemic events could be prolonged, possibly leading to more severe hypoxemia and brain damage or death. If hypoxemia during airway management is avoidable by modifying and improving the airway management with an iSGA-first strategy, outcomes might be significantly improved.

Blind intubation through an SGA is not always successful at 1st attempt^{4,5,6}. Use of a flexible scope to facilitate intubation via an SGA should improve first attempt success rates, especially for the less experienced clinician⁷. Further studies on the iSGA-first strategy in unanticipated difficult airways are needed to evaluate the effectiveness of this airway procedure in that population.

References

1. Ochroch A.E, Holland J.E, Kush S et al. Assessment of laryngeal view: Percentage of glottis opening score vs Cormack and Lehane grading. *Can J Anesth* 1999;46:110:987-990
2. Levitan RM et al. Assessment of airway visualization. Validation of the percentage of glottis opening (POGO) scale. *Academic Emerg Med*. 1998;5:919-923
3. Isono S et al. Oxygenation, Not Intubation, Does Matter. *Anesthesiology* 2011;114:7-9
4. Pennant JH et al. Comparison of the endotracheal tube and laryngeal mask in airway management by paramedical personnel. *Anesth Analg* 1992;74:531-4
5. Eugene L.H, Goy R.M et al. Success of tracheal Intubation with Intubating Laryngeal Mask Airways. A Randomized Trial of the LMA Fastrach and LMA CTrach. *Anesthesiology* 2008;108:621-6
6. Michalek P et al. A comparison of the l-gel supra-glottic airway as a conduit for tracheal intubation with the intubating laryngeal mask airway: A manikin study. *Resuscitation* 2010;81:74-77
7. Hodzovic I et al. Fiberoptic intubation using three airway conduits in a manikin: the effect of operator experience. *Anaesthesia* 2007;62:591-597